

Intestinal Obstruction due to *Ascaris Lumbricoides* Infestation in Adult Presented as Lump in Right Iliac Fossa: A Rare Presentation

Mohan Lal Choudhary, Prema Ram Choudhary

*Senior Resident, (MS Gen Surgery), Dr. S.N. Medical College, Jodhpur, Rajasthan

**Assistant Professor, C.U. Shah Medical College, Surendranagar, Gujarat

Abstract

Ascaris lumbricoides [AL] is common resident of intestine especially low socioeconomic areas in the world and may cause medical, social & surgical problem. Ascariasis can cause serious intra-abdominal complications such as intestinal obstruction, biliary obstruction, pancreatitis, acute appendicitis, intestinal perforation etc. We report an adult with intestinal obstruction due to entangled mass of AL, presented as a lump in right iliac fossa, managed by laparotomy and manually passing worms into colon without enterotomy.

Keywords: Intestinal obstruction; Roundworm; *Ascaris lumbricoides*.

Introduction

Ascaris lumbricoides [AL] is the most common helminth affecting humans and causing important medical, surgical and social problems especially in the under-developing countries. AL infestation occurs in all age groups but more common in children of preschool age. Complication of AL has been reported include obstruction of the small intestine, intestinal volvulus and intussusception. Obstruction of intestinal tract by a mass of AL is one of the serious and lethal complications.[1] It is suggested that routine

deworming of all patients attending paediatric surgical outpatient clinics should be done to prevent worm infestation and its complications.[2]

Case Report

A 17-year-old male presented to us with abdominal distension, colicky abdominal pain, vomiting and not passing flatus and motion for last 3 days.

Examination

His pulse was 100/minute, BP 110/70 mmHg. Patient was febrile with toxic look. Examination revealed tenderness and guarding with ill-defined mass in right iliac fossa.

Investigation

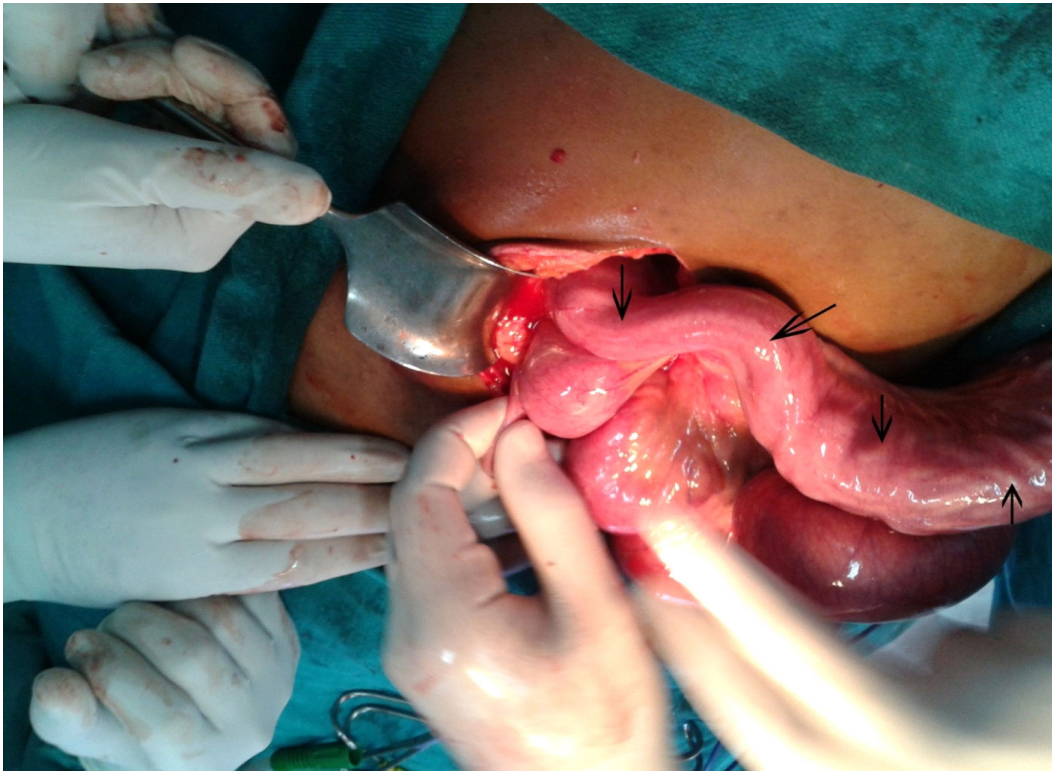
Blood investigation were within normal range except TLC 21000/mm³. X-ray plain abdomen shows multiple air-fluid levels without gas under diaphragm. USG shows mild ascites and fluid filled bowel loops.

Management

Patient resuscitated. On laparotomy, hundreds of palpable roundworms were impacting the distal 4 feet ileum and ileocaecal junction forming palpable entangled mass of worms (Fig 1). Rest of small gut was dilated and loosely packed with worms. Appendix was inflamed. Worms were massaged gently into the colon. Appendectomy was done.

Corresponding Author: Dr. Mohan Lal Choudhary, MS Gen Surgery, c/o - 65, sector 7, New power house road, shastri nagar, Jodhpur, rajasthan, Pin 342001.

Email: drmohanlalseervi@gmail.com

Figure 1

Postoperatively, after return of bowel movement, Tab albendazole 400 mg at bed time for 3 consecutive days was given. On next day worms started to pass along with stool. Postoperative recovery was uneventful and the patient was discharged on day 4. Tab albendazole 400 mg was given to all family members.

Discussion

AL is the largest and most prevalent of the human helminths. It is more prevalent in tropical and subtropical climates.[3] Man is infected by ingesting food contaminated with mature ova. The larvae escape from the ova in the duodenum and reach the lungs by the bloodstream, where further development occurs. They are again swallowed and reach the small intestine, where they reside mainly in the jejunum.[2] They live from stomach to ileocecal valve without causing any serious symptoms. When environment become intolerable for their living, they migrate to more appropriate areas of intestinal tract.[1]

Ascariasis can cause serious intra-abdominal complications such as intestinal obstruction, biliary obstruction, cholangiohepatitis, liver abscess, pan-creatitis, acute appendicitis, intestinal perforation, and granulomatous peritonitis and rarely duodenal stenosis.[3,4]

Intestinal obstruction may be due to:

- 1) obstruction of the lumen due to the entangled mass of worms;
- 2) spasmodic contraction of small bowel onto the mass of worms with effective obstruction at the ileocecal valve;
- 3) inflammation and matting of the loops of bowel at the site occupied by the worms; and
- 4) complications such as volvulus, intussusception, or band obstruction.[2]

Diagnosis and management of intestinal obstruction caused by ascariasis differ from other types of intestinal obstruction. It has a high morbidity and mortality, especially following surgical intervention.[3] Diagnosis with clinical symptoms and hematological investigation frequently is not possible. X-ray

may show air fluid levels. USG may show two pairs echogenic tubular structures (railway track/winding highway/triple line sign) longitudinally and bull's eye horizontally. Tubular structures may have active movements that could make diagnosis easily. USG is a simple and reliable method for diagnosis of AL obstruction.[1,5] Gastrograffin is used to diagnose complete intestinal obstruction as well as to relieve the partial obstruction caused by ascariasis. Being a hyperosmolar agent, it drags fluid to the intestinal lumen. This excess fluid in the vicinity around the worms probably separates them from each other. It also makes the worms more slippery, enabling them to pass beyond the region of obstruction, and it may also be swallowed by the worms, causing their dehydration and shrinkage. In suspected cases of bowel perforation, abdomen CT scan detects free intraperitoneal air.[3]

The subacute group may be managed conservatively by close monitoring and observation of the patient for the development of complications is essential. The conservative management includes: resuscitation with adequate fluid and electrolyte replacement to overcome the dehydration, nasogastric aspiration for decompression and to relieve distension or vomiting, and antibiotic coverage with analgesics. No antihelminthic should be given at this stage, as it may worsen the obstruction by increasing the size of the worm's bolus. Hypertonic saline enema has been recommended by some authors.[3]

Surgical intervention should be considered in:

- 1) intestinal obstruction showing signs of strangulation, perforation, or peritonitis,
- 2) complete intestinal obstruction as shown in gastrograffin follow-through study,
- 3) presence of intraperitoneal free air detected by abdominal CT scan,
- 4) suspected peritonitis or bowel gangrene during the period of observation,
- 5) unresolved partial intestinal obstruction after 24 hours of conservative management, and

- 6) complete intestinal obstruction developing after administration of antihelminthic drugs.[3]

According to Cole, in almost all cases the mass of worms can be fragmented and massaged into the colon, where they are rendered inactive. In cases of gangrene or perforation, resection and primary anastomosis should be performed. Opening the bowel in cases of ascariasis obstruction is said to be dangerous, as ascaris and its products are extremely irritating to the peritoneum and the suture line is not safe from penetration by the remaining ascarids. For this reason, the use of non-absorbable sutures for closure of the enterotomy has been recommended. Resection and ileostomy is reserved for patients where a short surgical procedure has to be carried out as a life-saving measure because of poor general condition.[2] After surgical treatment, the antihelminthic drugs can be given 3-5 days postoperatively after initiation of bowel movement and should be repeated after six weeks.[3]

Conclusion

Intestinal obstruction due to ascariasis is a serious disease with a high morbidity and mortality, especially postoperatively. The physicians treating patients with ascariasis should be aware of the abdominal complications, since a delay in its management may have a fatal outcome.

References

1. Ibrahim Yetim, Orhan Veli Ozkan, Ersan Semerci and Recep Abanoz. Rare cause of intestinal obstruction, *Ascaris lumbricoides* infestation: two case reports. *Cases Journal*. 2009; 2: 7970. doi: 10.4076/1757-1626-2-7970
2. A Mohta, D Bagga, C J Malhotra, R Chadha, A Kumar, and MP Arora. Intestinal obstruction due to roundworms. *Pediatr Surg Int*. 1993; 8: 226-228. <http://dx.doi.org/10.1007/BF00182524>.

3. Ashraf F Hefny, Yousif A Saadeldin, Fikri M Abuzidan. Management algorithm for intestinal obstruction due to ascariasis: a case report and review of the literature. *Turkish Journal of Trauma & Emergency Surgery*. 2009; 15(3): 301-305.
4. Kang JP, Cho YC, Young AS, et al. A Case of Biliary Ascariasis with Duodenal Stenosis. *Korean J Gastrointest Endosc*. 2011; 42: 442-445.
5. AC Ugwu, CC Ohagwu, AC Anakwue and OF Erundu. Parasitology: Appearances of Ascaris lumbricoides, Colon taeniasis, Cysticercus cellulosae Schistosoma haematobium, Dracunculus medinensis and Echinococcus granulosus infestations. *African Journal of Biotechnology*. 2008; 7(25): 4732-4736. DOI: 10.5897/AJB08.030.

Indian Journal of Trauma and Emergency Pediatrics (Formerly Indian Journal of Emergency Pediatrics)

Handsome offer for Indian Journal of Emergency Pediatrics subscribers

Subscribe **Indian Journal of Trauma and Emergency Pediatrics (Formerly Indian Journal of Emergency Pediatrics)** and get any one book or both books absolutely free worth Rs.400/-.

Offer and Subscription detail

Individual Subscriber

One year: Rs.1000/- (select any one book to receive absolutely free)

Life membership (valid for 10 years): Rs.5000/- (get both books absolutely free)

Books free for Subscribers of **Indian Journal of Trauma and Emergency Pediatrics (Formerly Indian Journal of Emergency Pediatrics)**. Please select as per your interest. So, don't wait and order it now.

Please note the offer is valid till stock last.

CHILD INTELLIGENCE

By Dr. Rajesh Shukla

ISBN: 81-901846-1-X, Pb, vi+141 Pages

Rs.150/-, US\$50/-

Published by **World Information Syndicate**

PEDIATRICS COMPANION

By Dr. Rajesh Shukla

ISBN: 81-901846-0-1, Hb, VIII+392 Pages

Rs.250/-, US\$50

Published by **World Information Syndicate**

Order from

Red Flower Publication Pvt. Ltd.

48/41-42, DSIDC, Pocket-II, Mayur Vihar, Phase-I

Delhi - 110 091 (India)

Tel: 91-11-65270068, 22754205, Fax: 91-11-22754205

E-mail: redflowerpppl@gmail.com, redflowerpppl@vsnl.net

Website: www.rfpppl.com